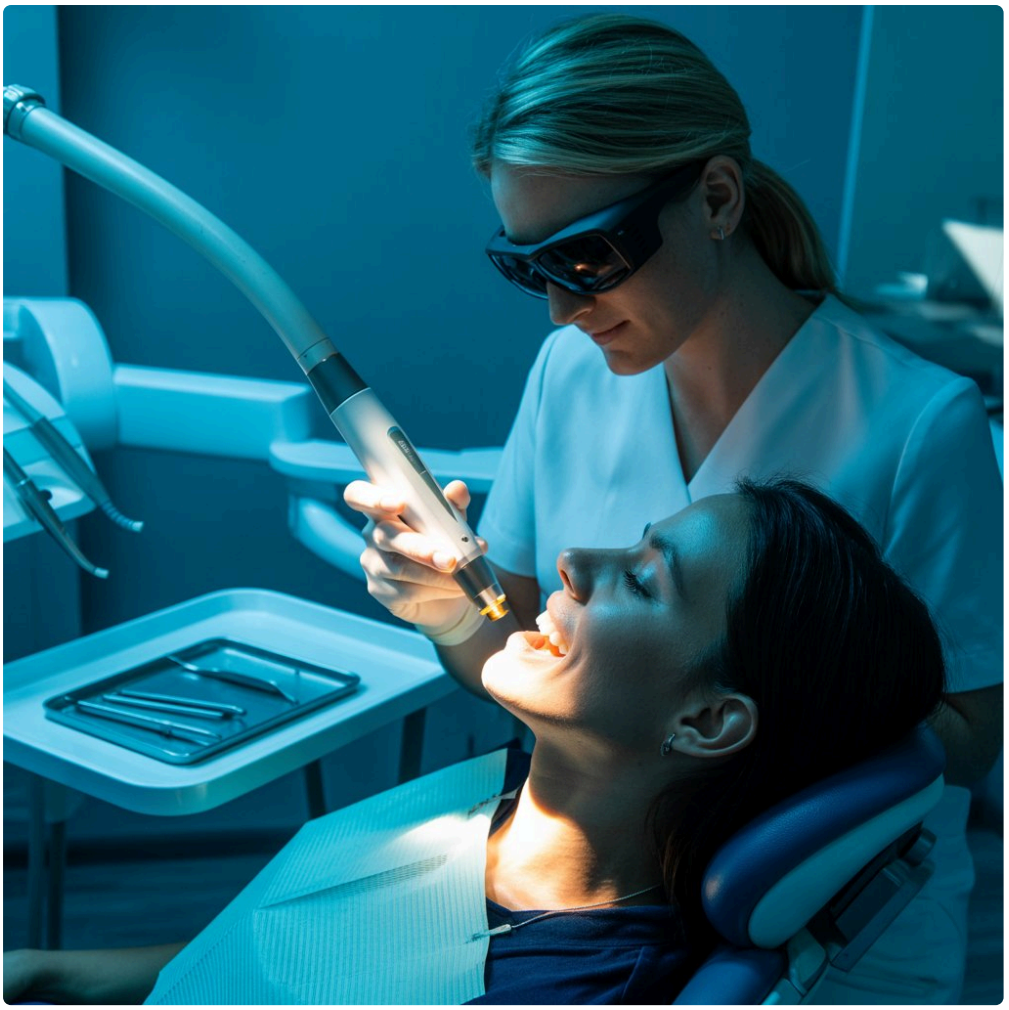

Oral trauma has a way of turning an ordinary day into a race against time. A fall on a wet kitchen floor, an elbow during a basketball game, a cycling accident, a cracked tooth from biting down on a cherry pit, any of these can leave a person bleeding, frightened, and unsure what to do next. In those first minutes, pain and panic tend to dominate. What often gets overlooked is how much the speed and quality of dental care shape the recovery that follows.

An Emergency Dentist does far more than stop immediate discomfort. The right treatment, delivered quickly, can preserve teeth, reduce infection risk, protect bone and soft tissue, improve healing, and prevent months of more complex care. When the injury involves the mouth, small delays can have outsized consequences. A tooth that might have been saved at 2 p.m. May be unsalvageable by evening. A lip laceration that looks minor can trap debris and become infected. A bite that feels only slightly off after trauma can signal a fracture that worsens with every meal.

Fast recovery after oral trauma is rarely about a single heroic procedure. More often, it depends on a series of good decisions made early: controlling bleeding, diagnosing the real extent of injury, stabilizing damaged structures, relieving pain without masking a serious problem, and setting up close follow-up while tissues heal. That is where emergency dental care earns its value.

Why the first hours matter so much

The mouth heals well, but it also works constantly. We talk, swallow, chew, clench, and breathe through tissues that may be bruised, torn, or fractured. That constant motion is one reason oral injuries can deteriorate quickly if they are not managed properly. It is also why recovery depends on early stabilization.

A displaced tooth is a good example. If a permanent tooth gets knocked out completely, the tiny periodontal ligament cells on the root surface begin to die once they dry out. Reimplantation may still be possible if action is quick, but the window is limited. Even when the tooth has only been loosened or pushed out of position rather than fully avulsed, prompt repositioning and splinting can make the difference between healing and long-term failure.

The same time sensitivity applies to fractures. A small enamel chip may be mostly cosmetic, but a crack extending into dentin or pulp can expose the tooth to bacteria and temperature sensitivity almost immediately. Left open, that injury often becomes more painful and more biologically complicated. A fracture of the jaw or alveolar bone brings another set of concerns, including occlusion changes, impaired chewing, and swelling that can worsen over the first day.

Soft tissue injuries deserve equal respect. The mouth bleeds dramatically because it has a rich blood supply. Patients often assume heavy bleeding means severe damage, and sometimes it does, but the real issue is not only volume. Embedded tooth fragments, contamination from pavement or sports surfaces, and missed through-and-through lacerations can all slow healing if they are not found and treated early.

What an emergency dentist evaluates right away

One of the most useful things an Emergency Dentist provides is calm, structured assessment. People tend to focus on the obvious injury, the broken front tooth, the bloody lip, the sharp edge cutting the tongue. A trained emergency clinician is looking wider than that.

They assess whether the tooth is fractured, loosened, intruded into the gum, partially displaced, or completely avulsed. They evaluate the surrounding bone, the bite relationship, the gums, cheeks, lips, tongue, and supporting structures. They ask how the injury happened because mechanism matters. A face-first fall from standing height raises different concerns than a puck to the mouth or a motor vehicle collision. They also consider whether there may be a concussion, ***Emergency Dentist*** facial fracture, or need for hospital-based care.

Radiographs are often part of this early workup, not because every case needs extensive imaging, but because dental trauma is frequently more complex than it appears. A tooth can look mostly intact and still have a root fracture. A lip cut may hide a piece of enamel. A patient who says, “It just feels a little weird when I bite,” may have a luxation injury or hairline crack that becomes significant under pressure.

That diagnostic step supports recovery in a very practical way. It prevents undertreatment. It also prevents overtreatment. Not every traumatized tooth needs root canal therapy, extraction, or aggressive restoration on day one. Sometimes the best choice is repositioning, splinting, protective sealing, medication guidance, and close monitoring. Judgment matters.

Pain control is only one part of urgent care

Many patients call because of pain, which is understandable. Still, pain relief alone is not the true goal. Oral trauma often produces a mix of nociceptive pain from bruising, thermal sensitivity from exposed dentin, pulpal inflammation, soft tissue tenderness, and muscle guarding from altered bite. An experienced clinician separates these layers rather than simply trying to blunt them.

Smoothing or covering a fractured edge can bring immediate relief because it removes a mechanical irritant. Repositioning a displaced tooth may reduce both pain and strain on the ligament. Draining a localized hematoma or addressing trapped debris in a wound can change the course of symptoms within hours. Sometimes a temporary restoration does more for comfort than medication alone.

There is also a strategic side to pain management. If someone leaves with only instructions to take over-the-counter analgesics but the bite is unstable or the pulp is exposed, the underlying problem keeps progressing. Fast recovery depends on reducing the source of injury, not only numbing its effects.

Saving teeth when minutes count

Dental trauma is one of the few situations where bystander action before arrival can affect the prognosis dramatically. A permanent tooth that has been knocked out is the classic example. If handled correctly, it may be replanted with a reasonable chance of retention. If scrubbed, wrapped in tissue, or left dry on a car dashboard, the chances drop sharply.

This is one of the rare moments where a short checklist is worth more than a paragraph.

1. Pick up the tooth by the crown, not the root.
2. If it is dirty, rinse it briefly with milk or saline, or clean water if nothing else is available.
3. If possible, place it back into the socket gently and have the person bite on clean gauze.
4. If reimplantation is not possible, keep the tooth moist in milk, saline, or inside the cheek if the person is alert and old enough to do so safely.
5. Get to an Emergency Dentist immediately.

That kind of intervention is not magic. Even with Emergency Dentist ideal handling, some replanted teeth later develop root resorption or pulpal complications. But when treatment is rapid, the odds improve significantly, and preserving a natural tooth even for several years can matter, especially in younger patients whose jaws are still developing.

Teeth that are not fully knocked out can often be saved as well. A luxated tooth may be gently repositioned and splinted. A crown fracture may be restored temporarily or definitively depending on extent. In some cases, the broken fragment can even be bonded back. Patients are often surprised by how conservative trauma care can be when they present early enough.

Stabilization speeds healing more than most people realize

Recovery after oral trauma is not just about what is repaired. It is also about what is stabilized so the body can do the rest. Teeth heal poorly if they keep moving. Soft tissue margins do not close neatly if a sharp tooth edge keeps reopening them. Jaw muscles do not relax if a shifted bite forces the patient to chew unevenly.

Splinting is a good example of stabilization done well. When a tooth is loose after injury, a flexible splint attached to adjacent teeth can protect it during the healing period without locking it so rigidly that physiologic movement is lost. Done appropriately, that balance supports the periodontal ligament and helps preserve function. The timing and duration depend on the type of injury. A simple subluxation may need only observation or a short period of support, while a root fracture or more severe luxation may require a different approach.

Temporary restorations play a similar role. A bonded material over exposed dentin, a protective covering over a fracture, or a provisional build-up to restore contour can reduce sensitivity, preserve tooth structure, and protect the pulp while the clinician watches how the tooth responds over time. Recovery often moves faster when the injured site is sheltered early.

There is also the issue of occlusion. After trauma, a single high spot can make a patient feel as though “all my teeth are wrong.” Even a minor bite discrepancy can lead to soreness in the tooth, surrounding ligament, jaw

joint, and muscles. Careful adjustment or interim management can make eating possible again, which helps overall recovery.

Soft tissue care often determines comfort in the days after injury

People tend to measure dental trauma by the tooth, but soft tissue management often shapes the patient's experience over the next week. A jagged incisor can repeatedly slice the lower lip. A small untreated laceration near the frenum may hurt every time the person smiles or speaks. A wound contaminated with dirt or asphalt can become inflamed and delay healing far more than expected.

An Emergency Dentist typically irrigates wounds thoroughly, checks for foreign material, and decides whether suturing is needed. They also inspect for tissue entrapment and assess whether a wound crosses important cosmetic or functional boundaries. Not every laceration belongs solely in a dental office, of course. If the injury is extensive, involves uncontrolled bleeding, facial asymmetry, suspected fractures, or airway concern, escalation to hospital or oral and maxillofacial surgery care is appropriate. Good emergency dental care includes recognizing those limits early.

One practical detail many patients appreciate is guidance on home care that fits real life. Soft foods, careful oral hygiene, saline rinses, avoiding straws in some cases, managing swelling with cold compresses early on, and knowing when to return, these simple measures can dramatically affect the next 48 to 72 hours. Recovery tends to be smoother when patients understand that cleanliness matters even if brushing near the area feels intimidating.

Children, athletes, and older adults all present differently

Trauma is never one-size-fits-all, and treatment decisions often shift with age and circumstance. In children, the main distinction is whether the injured tooth is primary or permanent. A baby tooth that has been driven into the gum may not be treated the same way as a permanent incisor in a teenager. The developing permanent tooth beneath it must be protected, which sometimes makes extraction or observation more sensible than aggressive repositioning.

For adolescents and adults in sports, timing and expectation are different. A young athlete may care just as much about returning to play as about the treatment itself. That creates tension between biologic healing and practical life demands. A mouthguard may become part of the recovery plan sooner than the patient expects, and return-to-play advice should be honest. A tooth that looks stable on day three may still be vulnerable to another blow.

Older adults introduce another set of variables. Bone density, existing crowns, bridges, implants, dry mouth from medications, and slower healing can all influence the plan. A crowned tooth that fractures at the margin after trauma may not have the same restorative options as an untouched tooth in a younger mouth. In some cases, the fastest path to comfort is not tooth preservation at all, but extraction followed by a staged replacement plan. Good emergency care means matching urgency with realism.

When rapid treatment prevents bigger problems later

One of the clearest benefits of seeing an Emergency Dentist promptly is the reduction in downstream complications. Trauma that seems minor in the moment can evolve. A tooth may discolor weeks later because the pulp lost vitality. A crack can propagate. A loosened tooth may tighten up normally or may become progressively more mobile if the ligament and bone support were more damaged than first believed.

Early treatment does not eliminate all of those risks, but it lowers them and, just as important, creates a record and a follow-up plan. That matters because dental trauma is often a story told over months, not hours. Teeth may need vitality testing over time. Radiographs may be repeated to look for root resorption, periapical change, or healing around fractures. Splints need removal at the right interval. Temporary restorations need reassessment. Symptoms that were absent at first can emerge later.

There is a practical financial side here too. Prompt care often costs less overall than delayed care. A simple repositioning and splint today may avert extraction, grafting, and implant planning later. Even when the final outcome is uncertain, trying to preserve options early usually pays off.

What recovery actually looks like after the first visit

Patients often expect either instant normalcy or immediate failure, when most recoveries fall somewhere in between. The first appointment addresses urgent issues, but the body still needs time. Swelling may peak over the first couple of days. Bruising can become more visible before it fades. Teeth that were hit may feel odd when biting for a while even if the prognosis is good. Soft tissues may tighten, then improve gradually as inflammation subsides.

An experienced clinician usually prepares the patient for this middle phase. That helps reduce unnecessary alarm and also sharpens awareness of true warning signs. If pain escalates instead of settling, if swelling becomes firm and pronounced, if fever appears, if the bite changes further, or if a tooth becomes dramatically darker or more mobile, follow-up should not wait.

The home instructions that matter most tend to be straightforward:

1. Eat a soft diet for the period advised, usually several days to a couple of weeks depending on the injury.
2. Keep the area clean with gentle brushing and any recommended rinse.
3. Avoid testing the injured tooth with hard foods, fingers, or tongue pressure.
4. Use medication exactly as directed and do not exceed dosing recommendations.
5. Return for scheduled reassessment even if things seem better.

That final point gets neglected. Trauma follow-up is not optional housekeeping. It is part of treatment. The tooth that feels quiet today may be declaring its real status a month from now.

The balance between speed and restraint

Fast recovery does not always come from doing the maximum amount of dentistry immediately. In trauma care, haste without judgment can create problems. Bonding a beautiful final restoration onto a tooth with an uncertain pulpal status may look satisfying on day one and fail strategically later. Extracting a traumatized tooth too early can close off salvage options. On the other hand, waiting too long to intervene can compromise tissues that needed urgent support.

That balance is where experience shows. A clinician who handles trauma regularly knows when to splint and when not to, when to refer, when a pulp cap has a fighting chance, when a crown-root fracture is restorable, and when the kindest plan is to stabilize the patient now and stage definitive treatment thoughtfully. Recovery is fastest when the first steps are decisive but not reckless.

I have seen patients walk in convinced they had lost a front tooth forever, only to leave with it repositioned, stabilized, and very much worth trying to save. I have also seen injuries dismissed elsewhere as simple chips that turned out to involve root fractures and embedded fragments in the lip. The difference was not technology or

theatrics. It was careful examination, appropriate urgency, and a treatment plan that respected how oral tissues actually heal.

Choosing the right emergency response

Not every dental office is set up for trauma care, and not every facial injury belongs in a dental chair. A true Emergency Dentist should be prepared to triage effectively, provide same-day care when indicated, and coordinate referral when the situation calls for oral surgery, endodontics, pediatric expertise, or hospital evaluation. That coordination supports recovery because it reduces delays between the acute event and the next necessary step.

For patients and families, the most useful mindset is simple: if a tooth is broken, loose, displaced, or knocked out, or if there is significant bleeding, swelling, or bite change after an injury, assume speed matters. Seek evaluation early. Preserve anything that broke off if possible. Keep the area clean and avoid improvising home fixes beyond basic first aid.

Oral trauma is disruptive, but it is not automatically catastrophic. With timely assessment, accurate diagnosis, and practical follow-up, many injuries heal better than patients expect. The work of an Emergency Dentist is not only to respond to the crisis in front of them. It is to preserve function, comfort, appearance, and options for the weeks and years that come after the accident. That is what fast recovery really means.

Vitality Dental
1220 Coit Rd # 106, Plano, TX 75075, United States
+1 972-645-4100

FAQ About Emergency Dentist

What counts as a dental emergency?

A knocked-out tooth, significant mouth injury, severe tooth pain, or painful swelling warrants prompt evaluation. Call your dentist and describe your symptoms so the office can advise you on how urgently you need care.

What should I do if I knock out a permanent tooth?

Call a dentist immediately. Handle the tooth by the crown, avoid touching the root, and keep it moist. If you cannot put it back into the socket easily, transport it in milk or a tooth-preservation solution. Bring it with you to the appointment.

Should I go to the emergency room for a dental emergency?

Seek emergency medical care right away if you have trouble breathing or swallowing, uncontrolled bleeding, or a serious facial injury. For an isolated tooth injury or toothache without those symptoms, call a dentist promptly for guidance.